

Back Pain in Children and Adolescents

Suraj Achar, MD, University of California San Diego School of Medicine, San Diego, California

Jarrod Yamanaka, MD, Fairview Sports and Orthopedic Care, Blaine, Minnesota

Back pain is a relatively common presenting symptom in children and adolescents. Typical causes include muscle strain or spasm, spinal deformities (e.g., Scheuermann kyphosis, adolescent idiopathic scoliosis), spondylolysis, bulging or herniated intervertebral disks, apophysitis of the iliac crest, and functional pain syndromes such as fibromyalgia. Spondyloarthropathies such as ankylosing spondylitis may present with low back pain and stiffness, which are often worse in the morning. Less common but more serious causes include malignancy and infections. The physical examination should include postural inspection, evaluation for tenderness, range of motion, strength testing, and testing for fractures and nerve impingement. Treatment for patients with muscle strain include relative rest, home-based exercises, physical therapy, and limited use of nonsteroidal anti-inflammatory drugs. If findings from the history and physical examination suggest underlying pathology, radiography and laboratory studies are indicated initially; magnetic resonance imaging, computed tomography, or a bone scan may be needed for further evaluation. It is generally accepted that the following factors warrant immediate evaluation: patient age younger than five years, symptoms persisting beyond four weeks, systemic symptoms, nighttime pain, bowel incontinence/urinary retention, or other neurologic symptoms. (*Am Fam Physician*. 2020;102(1):19-28. Copyright © 2020 American Academy of Family Physicians.)

Back pain is a relatively common condition in children. A 2011 Danish study found a prevalence of 28% to 48% in school-aged children, with increasing incidence in older adolescents.¹ Care was sought in less than one-third of cases.¹ One large cohort study found associations between back pain and age greater than 12 years, a family history of back pain, spending more than two hours per day studying or watching television, an uncomfortable school desk, widespread pain, and sleep problems.² Evidence is mixed on the effect of heavy backpacks.³ Back pain in children should be assessed carefully because it can limit participation in sports, activities, and school. An estimated 10% to 15% of affected children will develop chronic low back pain later in life.⁴

History

An accurate history is essential in differentiating etiologies of back pain. Timing, onset, severity, location, frequency, and characteristics of the pain (e.g., whether it radiates)

should be addressed. School-aged children should be asked about recent illness, trauma, and nonaccidental injuries. Symptoms that warrant urgent evaluation for rare conditions are listed in *Table 1*. Patients with spondyloarthropathy may have back stiffness in the morning or a family history of rheumatologic disorders.⁵ *Tables 2 and 3* present suggested approaches for the evaluation and management of common causes of acute and chronic back pain.

Physical Examination

Examination of children and adolescents with back pain begins with a visual inspection of the back and standing posture. Gait testing should include heel and toe walking; children with diskitis may refuse to walk. Spasticity, ataxia, muscle atrophy, and instability suggest spinal cord impingement or muscular dystrophy. Signs of midline defects, such as dimples, hemangiomas, or hair patches, suggest underlying congenital spinal lesions. Curvature or accentuated kyphosis may signal scoliosis, Scheuermann kyphosis, or moderate limb length discrepancy. Leg length discrepancies of less than 2 cm are normal and usually not symptomatic.^{6,7} Palpation of the spinous processes may elicit tenderness in children with spondylolysis, malignancy, or infection. Pain at the iliac crest may occur with apophysitis.⁸ Range of motion should be assessed (*Figure 1*) to determine whether the back pain worsens with lumbar extension (spondylolysis) or flexion (discogenic conditions).

Additional content at <https://www.aafp.org/afp/2020/0701/p19.html>.

CME This clinical content conforms to AAFP criteria for CME. See CME Quiz on page 11.

Author disclosure: No relevant financial affiliations.

Patient information: A handout on this topic is available at <https://familydoctor.org/backpack-safety>.

TABLE 1

Symptoms Warranting Urgent Evaluation in Children and Adolescents with Back Pain

Diagnosis	Symptoms	Special considerations	Evaluation	Management
Diskitis or vertebral osteomyelitis	Gradual onset of irritability and back pain without systemic toxicity; limping; refusal to crawl, walk, or bend forward	More common in children younger than 5 years	Radiographic findings may be normal initially, but within 2 to 3 weeks will show narrowing of intervertebral space MRI is best imaging modality to show disk and adjacent vertebral end plates and can help differentiate between diskitis and vertebral osteomyelitis	Antibiotics with activity against <i>Staphylococcus aureus</i> and <i>Kingella kingae</i>
Epidural abscess	Fever, neurologic deficits, spinal pain	Extremely rare in immunocompetent patients	Urgent MRI	Urgent referral to neurosurgery
Neoplasm	Unremitting nighttime pain, weight loss, myelopathic symptoms (e.g., gait instability, weakness)	History of previous malignancy	MRI Complete blood count, C-reactive protein level, erythrocyte sedimentation rate	Urgent referral to neurosurgery
Septic sacroiliitis	Fever, limping, pain over sacroiliac joint	Bimodal distribution: children 6 to 48 months of age and adolescents	MRI Laboratory test results consistent with infection	Antibiotics with activity against <i>S. aureus</i> and <i>K. kingae</i> ; aspiration and culture in patients who do not respond to antibiotics
Syringomyelia	Pain and stiffness in back and shoulders; symptoms worsen with postural changes or Valsalva maneuver	Cervical syringomyelia can be associated with Arnold-Chiari malformation	Contrast-enhanced MRI shows fluid-filled, gliosis-lined cavity within the spinal cord at C2-T1, and possibly congenital anomalies	Urgent referral to neurosurgery for patients with functional decline
Tethered cord syndrome	Back pain exacerbated by exercise, bladder dysfunction, calf muscle atrophy, diminished or absent deep tendon reflexes, dermatomal sensory loss, leg weakness	Progressive scoliosis	MRI Physical examination may reveal weak ankle dorsiflexion in older children (usually the earliest sign of motor dysfunction)	Urgent referral to neurosurgery
Transverse myelitis	Back pain, bowel or urinary dysfunction, sensorimotor deficits	Signs and symptoms may not correlate to a specific vertebral level	Urgent evaluation indicated: contrast-enhanced MRI, cerebrospinal fluid analysis	Urgent evaluation in emergency department

MRI = magnetic resonance imaging.

TABLE 2

Causes of Acute Back Pain in Children and Adolescents

Diagnosis	Presentation	Associated findings	Evaluation	Management
Herniated disk	Acute injury, low back pain radiating to leg	Radicular pain, positive straight leg raise test, decreased lumbar flexion	Radiography; MRI if no response to at least 6 weeks of conservative treatment	Relative rest, physical therapy; surgery for refractory cases
Muscle strain	Paraspinal pain	Muscle tenderness without radiation	No imaging required	Relative rest; physical therapy if persistent
Tumor or infection	Nighttime pain with fever or other generalized symptoms	Weight loss	Urgent radiography and MRI	Urgent evaluation in emergency department or by specialist
Vertebral fracture	Acute injury, focal midline pain	Other injuries, radicular pain, weakness	Urgent radiography and MRI	Urgent evaluation in emergency department

MRI = magnetic resonance imaging.

TABLE 3

Causes of Chronic Back Pain in Children and Adolescents

Diagnosis	Presentation	Associated findings	Evaluation	Management
Fibromyalgia and chronic widespread pain	Generalized widespread pain lasting at least 3 months with fatigue, nonrestorative sleep, and/or cognitive symptoms; tenderness to touch and sensitivity to sounds, lights, and smells	Most common in adolescents; functional illness is rare in children younger than 9 years; symptoms not limited to back	2010 American College of Rheumatology criteria* may replace older criteria	Multidisciplinary approach: education, exercise, cognitive behavior therapy, and optional pharmacotherapy, including tricyclic antidepressants
I Idiopathic scoliosis	Progressive constant pain with associated spinal deformity	Older age	Full spine radiography; consider other causes of back pain, including spondylolysis	Referral for all children younger than 12 years and for those with progressive scoliosis, significant pain, structural defects (hemivertebra), or Cobb angle > 20 degrees (especially > 40 degrees)
Iliac crest apophysitis	Tender area along iliac crest; pain (usually gradually worsening) with activity, especially running, jumping, kicking, or twisting	Skeletally immature 12- to 17-year-old patient; higher risk in those with tight hip or thigh muscles	Point-of-care ultrasonography showing tenderness with sonopalpation (i.e., palpation with the ultrasound probe)	Relative rest, icing or nonsteroidal anti-inflammatory drugs as needed; exercises, stretching, and possibly physical therapy
Inflammatory spondyloarthropathy	History of uveitis, polyarthritis, or stiffness	Morning stiffness, sacroiliac joint tenderness	Radiography, human leukocyte antigen B27 and rheumatoid factor testing, erythrocyte sedimentation rate, C-reactive protein level	Referral to pediatric rheumatologist
Scheuermann kyphosis	Stooped posture, upper back pain	Rigid kyphosis	Radiography and MRI for severe symptoms refractory to physical therapy	Reassurance, physical therapy; surgical referral for limitations in breathing or refractory pain
Spondylolysis	Pain with lumbar extension that may radiate down the leg	Hamstring tightness, positive stork test, reduced range of motion with lumbar extension	Radiography; MRI if negative or concern for active stress fracture	Relative rest, physical therapy; bracing for constant pain

MRI = magnetic resonance imaging.

*—Criteria are described in Ting TV, Barnett K, Lynch-Jordan A, et al. 2010 American College of Rheumatology adult fibromyalgia criteria for use in an adolescent female population with juvenile fibromyalgia. *J Pediatr.* 2016;169:181-187.e1.

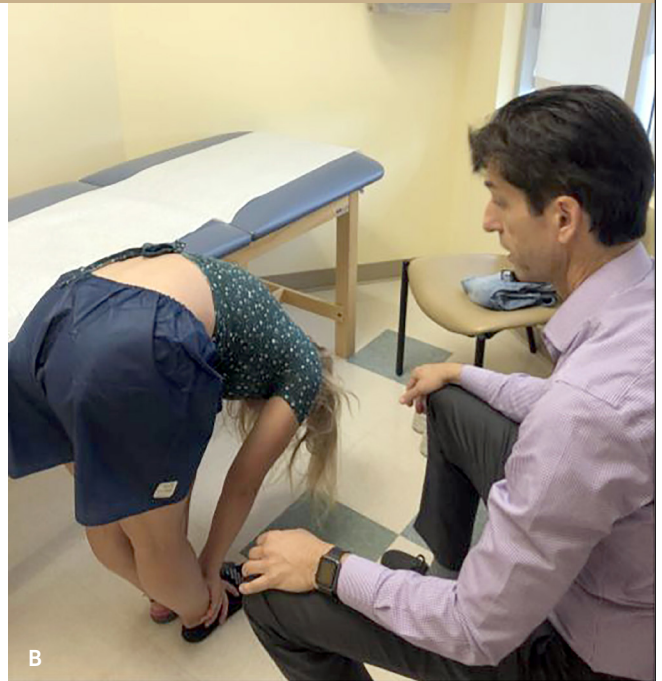
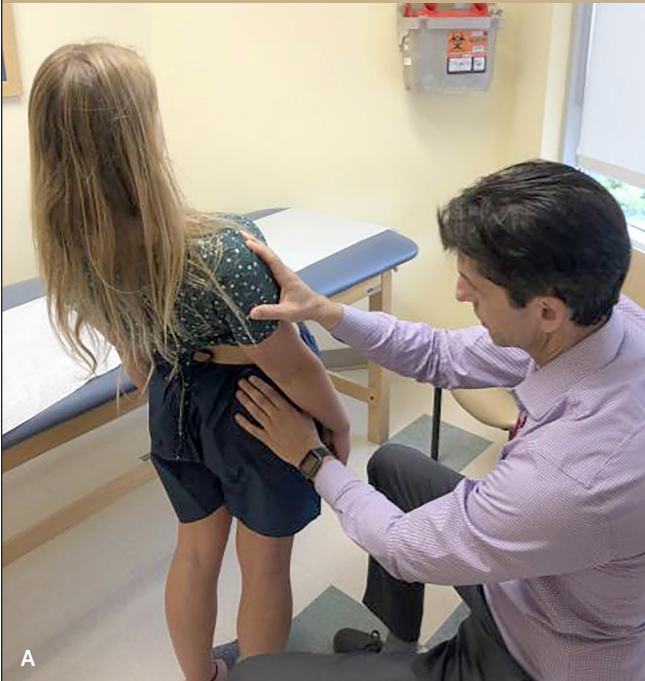Strength testing of the hips, knees, and ankles can evaluate for weakness related to pain or neuropathy. Dermatoma numbness and paresthesias suggest a nerve root lesion. Patellar and Achilles reflexes should be assessed, and a Babinski test may be performed to evaluate for upper motor neuron injury. The slump test (*Figure 2*) and straight leg raise test evaluate for sciatica; pain radiating to the gluteal area or down the leg indicates a positive test. In the Patrick (FABER) test, the examiner flexes, abducts, and externally rotates the patient's hip to stress the sacroiliac joint (*eFigure A*). Ipsilateral pain elicited by this maneuver indicates sacroiliitis, which in turn suggests ankylosing spondylitis. The Thomas test can be performed to determine hip flexor tightness. With the patient in the supine position, the examiner uses both hands to bring one knee to the chest. The test is positive

if the contralateral leg lifts off the table. In the stork test, the patient stands on one leg and hyperextends the lumbar spine (*Figure 3*); ipsilateral pain suggests spondylolysis, although the sensitivity (50% to 73%) and specificity (17% to 32%) are low.⁹ Lastly, quadriceps and hamstring tightness should be assessed; inflexibility is associated with spondylolysis and typically worsens as children progress to adolescence.^{9,10}

Imaging

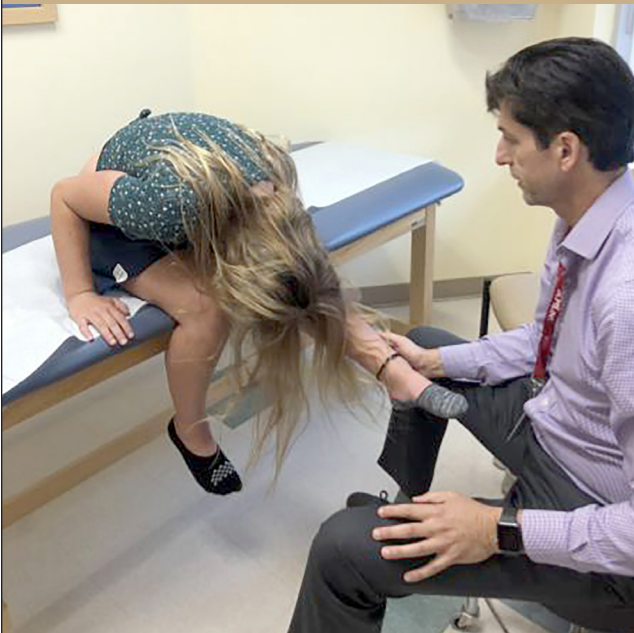Guidelines from the American College of Radiology state that imaging in children and adolescents can be delayed unless the patient has abnormal neurologic findings or pain that occurs at night, radiates, or persists beyond four weeks.¹¹ Plain radiography should be performed in patients with any of these findings.¹² Anteroposterior and lateral

FIGURE 1



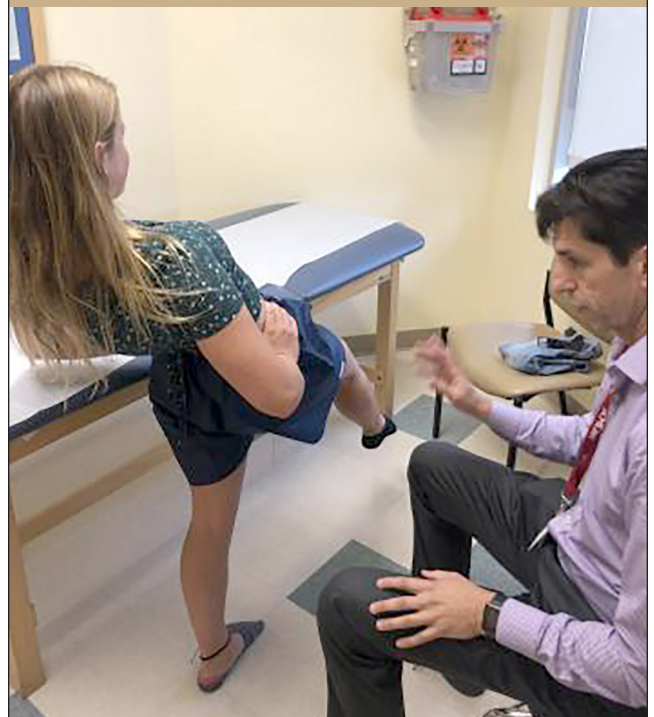Positions for evaluating low back pain. (A) Lumbar extension. (B) Lumbar flexion.

FIGURE 2



The slump test evaluates for sciatica. The patient flexes the spine into a slumped position and lifts the leg. A positive test elicits ipsilateral pain to the gluteal area and possibly down the leg in a dermatomal fashion. The slump test is more sensitive for sciatica than the straight leg raise test.

FIGURE 3



The stork test evaluates for spondylolysis. A positive test elicits ipsilateral pain with the one-legged stance while the lumbar region is hyperextended.

views are often sufficient, even when evaluating for spondylolysis.¹³ Oblique views double the radiation exposure and do not significantly improve sensitivity; therefore, they are no longer recommended in the evaluation of spondylolysis.¹⁴

Magnetic resonance imaging (MRI) should be considered for patients with localized pain who have normal radiographic findings. MRI can detect tumors, infections, and disk herniation, and it can assess for edema in the pars interarticularis region, which is consistent with acute spondylolysis.^{12,14} A bone scan may be indicated if MRI findings are inconclusive or in children with diffuse back pain. However, bone scans do not detect soft tissue tumors or infections that do not stimulate bone metabolism, and therefore may miss a critical condition. Computed tomography (CT) shows bony architecture and soft tissues but does not show marrow elements. CT can be performed quickly and generally does not require sedation, but it may expose children to significant ionizing radiation.

Laboratory Testing

A complete blood count with differential, erythrocyte sedimentation rate (ESR), and C-reactive protein (CRP) level should be obtained if there is concern for malignancy or inflammatory conditions (e.g., spondyloarthropathies, juvenile rheumatoid arthritis, infections). Although an elevated ESR (more than 20 mm per hour) and/or CRP level (more than 1 to 2 mg per dL [10 to 20 mg per L]) is nearly 95% sensitive for osteomyelitis, the specificity is low (60%).¹⁵ The presence of human leukocyte antigen B27 is strongly associated with seronegative spondyloarthropathy (ankylosing spondylitis, reactive arthritis, and spondylitis associated with psoriasis and inflammatory bowel disease), but because of high false-positive rates, testing should be reserved for patients with high clinical suspicion, such as those with morning stiffness, night pain that improves with exercise, or sacroiliac pain. Other tests (e.g., rheumatoid factor, antinuclear antibodies, antistreptolysin O, Lyme disease testing) could be considered in the presence of associated findings, but they generally are not useful.¹⁶ Axial spondyloarthropathy should be considered if clinical symptoms occur and MRI findings are negative; this condition is associated with elevated ESR and/or CRP levels in approximately 40% of cases.¹⁷ If there is concern for axial spondyloarthropathy, consultation with a pediatric rheumatologist may be warranted.

Treatment

The approach to treating back pain in children and adolescents depends on the etiology and clinical course. For benign causes, relative rest, limited use of nonsteroidal anti-inflammatory drugs, and close follow-up without imaging is

warranted. Physical therapy can be helpful for core strengthening and lower extremity flexibility, and Pilates is potentially useful based on its positive effects on quality of life in patients with juvenile idiopathic arthritis¹⁸ (Figure 4). Treatments for specific conditions are addressed below. An algorithm for the evaluation and treatment of back pain in children and adolescents is presented in Figure 5.¹⁹ Continued monitoring and close follow-up within four weeks can potentially diagnose serious conditions early.

Common Causes

LUMBAR MUSCLE STRAIN OR SPASM

Although published incidence studies are limited, many cases of low back pain in children who present to a primary care setting are attributed to a lumbar muscle strain or spasm.²⁰ Muscle spasm may be related to growth, resulting in tight hamstrings and quadriceps that cause a posterior pelvic tilt. An association between heavy backpacks and



FIGURE 4

Pilates exercises can help with core strengthening and assist in rehabilitating low back pain.

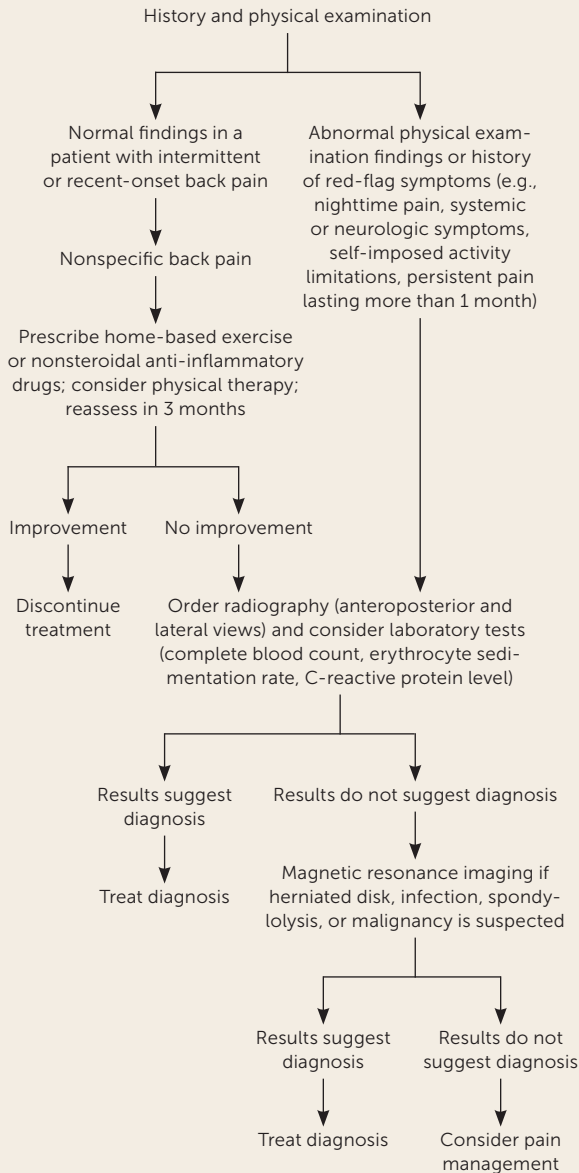
back pain is controversial. However, the American Academy of Pediatrics recommends that backpacks not exceed 10% to 20% of the child's weight.^{3,21} Most cases of lumbar strain or nonspecific back pain respond to conservative management, including activities as tolerated, postural

exercises, and lower extremity stretching.²⁰ Pain usually resolves within a few weeks.²⁰

SPONDYLOLYSIS AND SPONDYLOLISTHESIS

Spondylolysis is a stress injury to the pars interarticularis. Spondylolisthesis occurs when there is a bilateral pars injury with translation of one vertebral body over another (Figure 6). Spondylolysis affects up to 6% of all children, but the incidence among athletes is unclear.^{4,22} The primary sites include L5 (71% to 95%) and L4 (5% to 23%), but it can occur at any level.²² Although spondylolysis is common among athletes whose sports require repetitive lumbar extension (e.g., gymnasts, football linemen, divers, baseball players), it can occur in any athlete.¹¹ Pain tends to be focal, may be associated with tenderness to palpation of the spinous

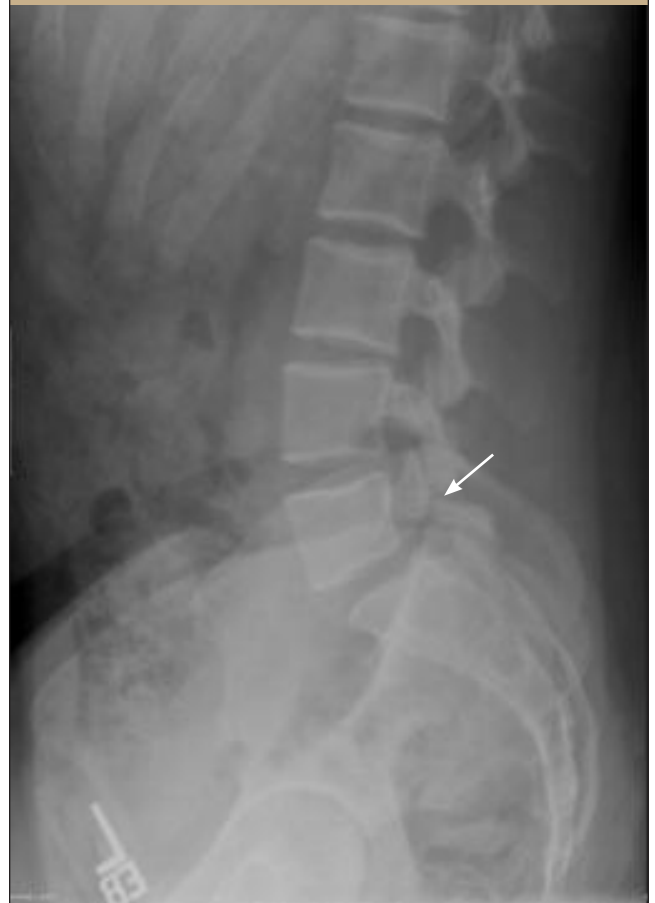FIGURE 5



Algorithm for evaluation and treatment of back pain in children and adolescents.

Information from reference 19.

FIGURE 6



Radiograph of a patient with spondylolisthesis. Note the bilateral L5 pars defects (arrow) and mild anterolisthesis at L5-S1.

PEDIATRIC BACK PAIN

process, and worsens with extension. A positive stork test is concerning for spondylolysis; other associated findings include tight quadriceps and hamstrings.²³ Anteroposterior and lateral radiographs may show a fracture of the pars interarticularis.²² If radiographic findings are negative, patients can be treated conservatively for six weeks.²² If pain persists, MRI sequenced to detect bone marrow edema in the pedicle and pars region is the preferred next step; single-photon emission CT is indicated if MRI is not available.^{11,22}

More than 90% of patients with spondylolysis respond to conservative treatment, such as relative rest, flexibility exercises for the quadriceps and hamstrings, and core strengthening with a guided exercise program.^{23,24} Although bracing has not been conclusively proven to accelerate healing, it can be helpful for pain control if other conservative measures are ineffective.²⁴ If bracing is indicated, a low thoracolumbar orthosis (*Figure 7*) is as effective as a high thoracolumbar orthosis.²⁵ The duration of bracing depends on symptom

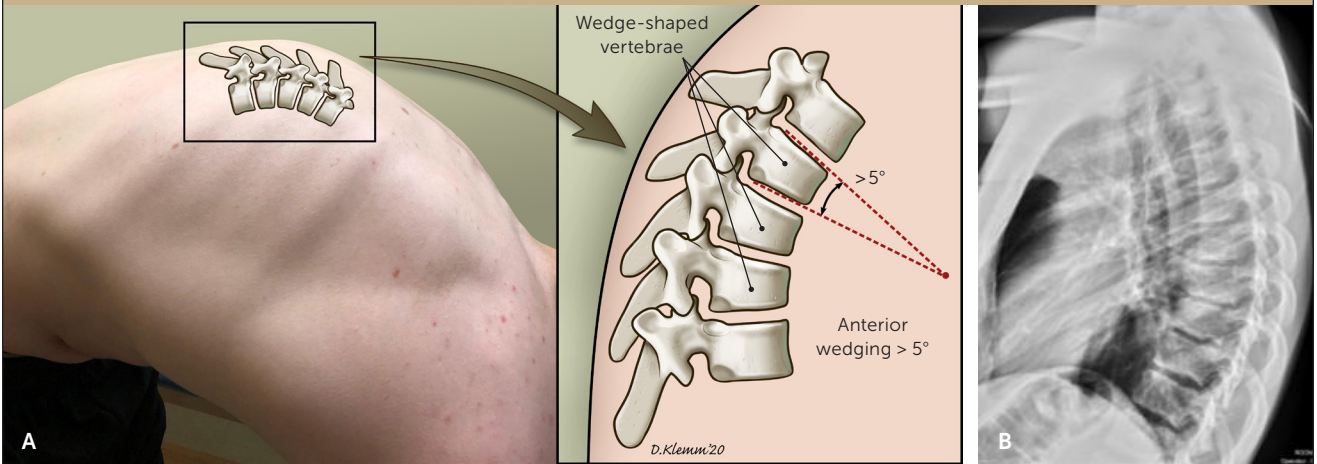
response: It should be tapered when the patient is pain free, regardless of radiographic healing.²⁶ Research has not shown that limited use of nonsteroidal anti-inflammatory drugs delays bone healing in children, as has been postulated in adults.²⁷ Case studies have shown that acute fractures that do not improve with six weeks of conservative management may respond to transcutaneous electrical nerve stimulation²⁶ (*Figure 8*). Return to activity should be gradual over approximately five months.²⁸ Surgical management is limited to children who progress to grade 3 spondylolisthesis (50% to 75% vertebral translation), whose pain persists longer than six months, or who develop additional symptoms that are refractory to conservative management.²²

SCHEUERMANN KYPHOSIS

Scheuermann kyphosis is osteochondrosis that presents as an abnormality of the vertebral epiphyseal growth plates. Criteria include three or more adjacent vertebrae wedged more than 5 degrees and disk space that narrows in the thoracic region^{29,30} (*Figure 9*). Because there is no diagnostic standard for Scheuermann kyphosis, prevalence rates vary widely.^{29,30} It can be noted in children as young as eight to 12 years who present with a postural deformity that does

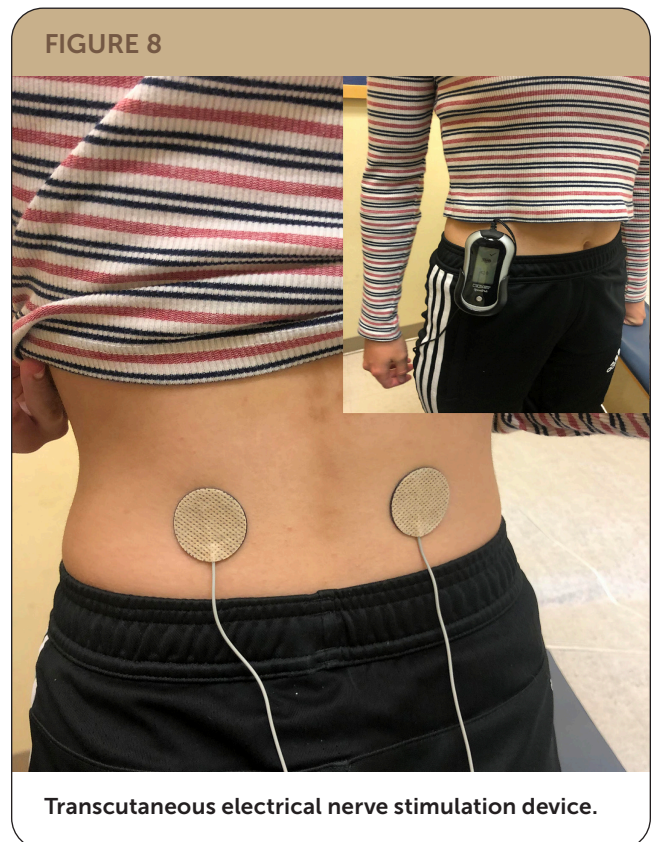

FIGURE 9



Scheuermann kyphosis. (A) Patients have three or more adjacent vertebrae wedged more than 5 degrees and disk space that narrows in the thoracic region. **(B)** Radiography shows mild anterior wedge compression deformities of T7-T9 with no displaced fractures.

Photo illustration by Dave Klemm

not resolve with extension or by lying down. Symptoms include gradual onset of pain without trauma over the deformity. Pain can worsen at the end of the day and is relieved with rest.²⁹ Treatment is generally conservative without bracing or orthopedic interventions. Indications for orthopedic intervention include pain that does not respond to nonoperative treatment, neural impairment, and severe deformity (more than 80 degrees) that restricts pulmonary function.^{30,31} Pain tends to improve with skeletal maturity.³²

SCOLIOSIS

Adolescent idiopathic scoliosis is a lateral curvature of the spine of more than 10 degrees. It occurs in 2% to 3% of adolescents.³³ Back pain associated with this condition is linked to increasing age, injuries, and severity of curvature.³⁴ Another underlying condition is present in 10% to 35% of children with scoliosis and back pain, such as spondylolysis, spondylolisthesis, Scheuermann kyphosis, or disk herniation^{35,36}; therefore, a careful history and physical examination with appropriate imaging should be performed to evaluate for these and other etiologies. A previous article in *American Family Physician* addressed the evaluation and treatment of patients with isolated adolescent idiopathic scoliosis.³⁷ Referral to

SORT: KEY RECOMMENDATIONS FOR PRACTICE

Clinical recommendation	Evidence rating	Comments
Constant pain, bony tenderness, abnormal neurologic findings, or back pain that occurs at night may warrant further evaluation in children, including imaging and possibly laboratory testing. ^{10,11,13,14}	C	Expert opinion and consensus guideline in the absence of clinical trials
Radiography with anteroposterior and lateral views should be ordered for patients with suspected spondylolysis. ¹⁴	B	Systematic review of imaging for spondylolysis
Most patients with spondylolysis respond to conservative treatment, including relative rest, quadriceps and hamstrings flexibility exercises, and core strengthening with a guided exercise program. ^{23,24}	B	Meta-analysis and prospective cohort study
Treatment of Scheuermann kyphosis is generally conservative, without bracing or orthopedic interventions unless the deformity is severe (more than 80 degrees), progressive, or restricts pulmonary function. ^{30,31}	C	Prospective comparative study of respiratory measures and clinical review

A = consistent, good-quality patient-oriented evidence; **B** = inconsistent or limited-quality patient-oriented evidence; **C** = consensus, disease-oriented evidence, usual practice, expert opinion, or case series. For information about the SORT evidence rating system, go to <https://www.aafp.org/afpsort>.

a scoliosis center is indicated if symptoms do not respond to a conservative exercise program.

LUMBAR DISK HERNIATION

Although disk abnormalities on MRI can be common, symptomatic lumbar disk herniations with nerve root impingement are rare.³⁸ Most adolescents with disk herniation (60%) report that an acute event precipitated the pain.³⁸ Although the straight leg raise and slump tests were developed for adults, these tests have been positively correlated with disk herniation in pediatric populations.³⁹ The slump test is more sensitive than the straight leg raise test in patients with lumbar disk herniation (84% vs. 52%, respectively).³⁹ Initial imaging in patients with suspected disk herniation should include lumbar radiographs (anteroposterior and lateral).³⁸ However, MRI is the preferred diagnostic modality and can help evaluate for soft tissue tumors, syringomyelia, or other spinal abnormalities.³⁹ Timing of imaging depends on the concern for other causes of pain, as well as the severity and duration of symptoms. Treatment includes relative rest and physical therapy with lower extremity and core strengthening. Only refractory cases require surgery. If the patient does not improve as expected with conservative treatment, CT should be considered to assess for an occult apophyseal ring fracture, which occurs in the immature lumbar spine when fibers of the intervertebral disk attach to an incompletely fused posterior vertebral body.⁴⁰ These fractures may require surgery.

This article updates a previous article on this topic by Bernstein and Cozen.⁴¹

Data Sources: We searched PubMed, the Cochrane database, the Cochrane Central Register of Controlled Trials, and the National Guideline Clearinghouse using the key words pediatric back pain, Scheuermann's disease, iliac apophysitis, pediatric spondylolysis, spondylolisthesis, pediatric disc herniation, and pediatric lumbar pain. The search included meta-analyses, systematic reviews, randomized controlled trials, clinical trials, guidelines, and diagnostic studies. Search dates: March 2019 to April 2020.

The authors thank Haley Nau and Bri Blonigan for their help with the photos.

The Authors

SURAJ ACHAR, MD, CAQSM, FAAFP, is a faculty member at 360 Sports Medicine at Rady Children's Hospital and a professor of family medicine and public health at the University of California San Diego School of Medicine.

JARROD YAMANAKA, MD, CAQSM, is a sports medicine physician at Fairview Sports and Orthopedic Care, Blaine, Minn.

Address correspondence to Suraj Achar, MD, 9500 Gilman Dr., La Jolla, CA 92023 (email: sachar@health.ucsd.edu).

Reprints are not available from the authors.

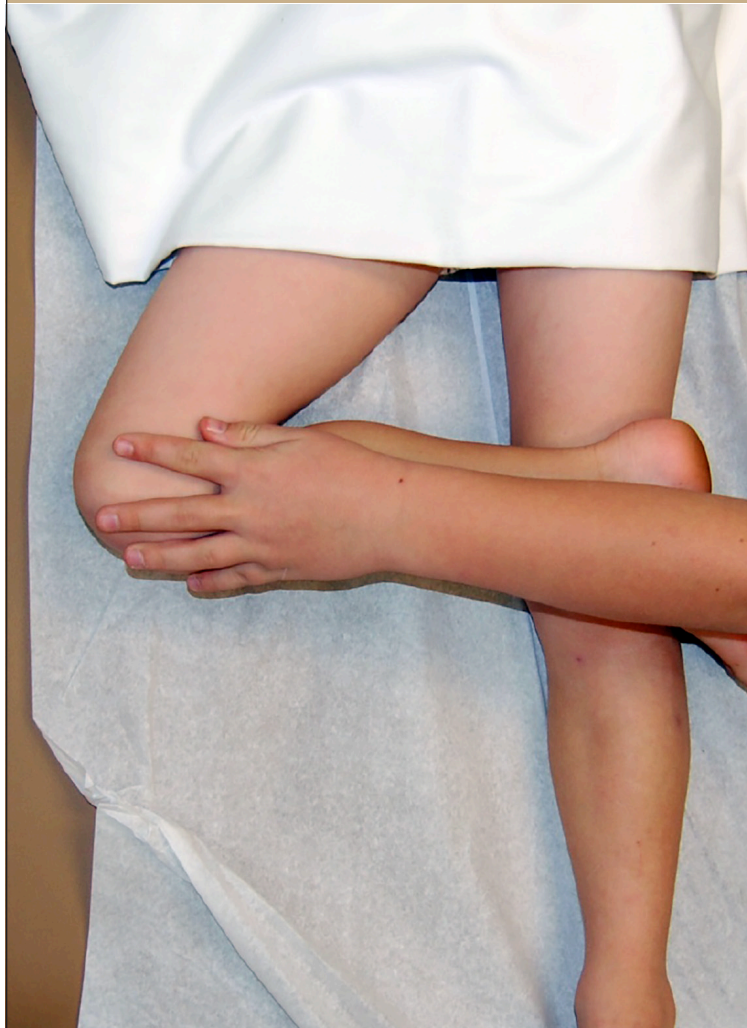References

1. Kjaer P, Wedderkopp N, Korsholm L, et al. Prevalence and tracking of back pain from childhood to adolescence. *BMC Musculoskelet Disord*. 2011;12(1):98.
2. Szita J, Boja S, Szilagyi A, et al. Risk factors of non-specific spinal pain in childhood. *Eur Spine J*. 2018;27(5):1119-1126.
3. Dockrell S, Simms C, Blake C. Schoolbag weight limit: can it be defined? *J Sch Health*. 2013;83(5):368-377.
4. Sundell CG, Bergström E, Larsén K. Low back pain and associated disability in Swedish adolescents. *Scand J Med Sci Sports*. 2019;29(3):393-399.
5. Adrovic A, Barut K, Sahin S, et al. Juvenile spondyloarthropathies. *Curr Rheumatol Rep*. 2016;18(8):55.
6. Raczkowski JW, Daniszewska B, Zolynski K. Functional scoliosis caused by leg length discrepancy. *Arch Med Sci*. 2010;6(3):393-398.
7. Gordon JE, Davis LE. Leg length discrepancy: the natural history (and what do we really know). *J Pediatr Orthop*. 2019;39(6 suppl 1):S10-S13.
8. Kivel CG, d'Hemecourt CA, Micheli LJ. Treatment of iliac crest apophysitis in the young athlete with bone stimulation: report of 2 cases. *Clin J Sport Med*. 2011;21(2):144-147.
9. Alqarni AM, Schneiders AG, Cook CE, et al. Clinical tests to diagnose lumbar spondylolysis and spondylolisthesis: a systematic review. *Phys Ther Sport*. 2015;16(3):268-275.
10. Lee SY, Lee SH, Chung CY, et al. Age-related changes in physical examination and gait parameters in normally developing children and adolescents. *J Pediatr Orthop B*. 2013;22(2):153-157.
11. Booth TN, Iyer RS, Falcone RA Jr, et al.; Expert Panel on Pediatric Imaging. ACR Appropriateness Criteria: back pain—child. *J Am Coll Radiol*. 2017;14(5S):S13-S24.
12. Ramírez N, Olivella G, Valentín P, et al. Are constant pain, night pain, or abnormal neurological examination adequate predictors of the presence of a significant pathology associated with pediatric back pain? *J Pediatr Orthop*. 2019;39(6):e478-e481.
13. Calloni SF, Huisman TA, Poretti A, et al. Back pain and scoliosis in children: when to image, what to consider. *Neuroradiol J*. 2017;30(5):393-404.
14. Tofte JN, CarlLee TL, Holte AJ, et al. Imaging pediatric spondylolysis: a systematic review. *Spine (Phila Pa 1976)*. 2017;42(10):777-782.
15. Dartnell J, Ramachandran M, Katchburian M. Haematogenous acute and subacute paediatric osteomyelitis: a systematic review of the literature. *J Bone Joint Surg Br*. 2012;94(5):584-595.
16. McGhee JL, Burks FN, Sheckels JL, et al. Identifying children with chronic arthritis based on chief complaints: absence of predictive value for musculoskeletal pain as an indicator of rheumatic disease in children. *Pediatrics*. 2002;110(2 pt 1):354-359.
17. van Tubergen A. The changing clinical picture and epidemiology of spondyloarthritis. *Nat Rev Rheumatol*. 2015;11(2):110-118.
18. Mendonça TM, Terreri MT, Silva CH, et al. Effects of Pilates exercises on health-related quality of life in individuals with juvenile idiopathic arthritis. *Arch Phys Med Rehabil*. 2013;94(11):2093-2102.
19. Feldman DS, Straight JJ, Badra MI, et al. Evaluation of an algorithmic approach to pediatric back pain. *J Pediatr Orthop*. 2006;26(3):353-357.
20. Yang S, Werner BC, Singla A, et al. Low back pain in adolescents: a 1-year analysis of eventual diagnoses. *J Pediatr Orthop*. 2017;37(5):344-347.
21. American Academy of Pediatrics. Backpack safety. November 21, 2015. Accessed November 7, 2019. <https://www.healthychildren.org/English/safety-prevention/at-play/Pages/Backpack-Safety.aspx>
22. Bouras T, Korovessis P. Management of spondylolysis and low-grade spondylolisthesis in fine athletes. A comprehensive review. *Eur J Orthop Surg Traumatol*. 2015;25(suppl 1):S167-S175.
23. Sato M, Mase Y, Sairyo K. Active stretching for lower extremity muscle tightness in pediatric patients with lumbar spondylolysis. *J Med Invest*. 2017;64(1.2):136-139.

PEDIATRIC BACK PAIN

24. Klein G, Mehlman CT, McCarty M. Nonoperative treatment of spondylolysis and grade I spondylolisthesis in children and young adults: a meta-analysis of observational studies. *J Pediatr Orthop*. 2009;29(2):146-156.
25. Virkki E, Holstila M, Mattila K, et al. Radiographic outcomes of immobilization using Boston brace for pediatric spondylolysis [published online January 1, 2020]. *Scand J Surg*. Accessed April 20, 2020. <https://journals.sagepub.com/doi/full/10.1177/1457496919896998>
26. Panteliadis P, Nagra NS, Edwards KL, et al. Athletic population with spondylolysis: review of outcomes following surgical repair or conservative management. *Global Spine J*. 2016;6(6):615-625.
27. Wheatley BM, Nappo KE, Christensen DL, et al. Effect of NSAIDs on bone healing rates: a meta-analysis. *J Am Acad Orthop Surg*. 2019;27(7):e330-e336.
28. Grazina R, Andrade R, Santos FL, et al. Return to play after conservative and surgical treatment in athletes with spondylolysis: a systematic review. *Phys Ther Sport*. 2019;37:34-43.
29. Horn SR, Poorman GW, Tishelman JC, et al. Trends in treatment of Scheuermann kyphosis: a study of 1,070 cases from 2003 to 2012. *Spine Deform*. 2019;7(1):100-106.
30. Tsirikos AI, Jain AK. Scheuermann's kyphosis; current controversies. *J Bone Joint Surg Br*. 2011;93(7):857-864.
31. Lorente A, Barrios C, Lorente R, et al. Severe hyperkyphosis reduces the aerobic capacity and maximal exercise tolerance in patients with Scheuermann disease. *Spine J*. 2019;19(2):330-338.
32. Huq S, Ehresman J, Cottrill E, et al. Treatment approaches for Scheuermann kyphosis: a systematic review of historic and current management. *J Neurosurg Spine*. 2020;32(2):235-247.
33. Teles AR, Ocay DD, Bin Shebreen A, et al. Evidence of impaired pain modulation in adolescents with idiopathic scoliosis and chronic back pain. *Spine J*. 2019;19(4):677-686.
34. Konieczny MR, Senyurt H, Krauspe R. Epidemiology of adolescent idiopathic scoliosis. *J Child Orthop*. 2013;7(1):3-9.
35. Ramirez N, Johnston CE, Browne RH. The prevalence of back pain in children who have idiopathic scoliosis. *J Bone Joint Surg Am*. 1997;79(3):364-368.
36. Ramirez N, Olivella G, Cuneo A, et al. Prevalence and clinical relevance of underlying pathological conditions in painful adolescent idiopathic scoliosis: a MRI-based study [published online February 18, 2020]. *Spine Deform*. Accessed April 20, 2020. <https://link.springer.com/article/10.1007/s43390-020-00065-w>
37. Kuznia AL, Hernandez AK, Lee LU. Adolescent idiopathic scoliosis: common questions and answers. *Am Fam Physician*. 2020;101(1):19-23. Accessed May 6, 2020. <https://www.aafp.org/afp/2020/0101/p19.html>
38. Lavelle WF, Bianco A, Mason R, et al. Pediatric disk herniation. *J Am Acad Orthop Surg*. 2011;19(11):649-656.
39. Cahill KS, Dunn I, Gunnarsson T, et al. Lumbar microdiscectomy in pediatric patients: a large single-institution series. *J Neurosurg Spine*. 2010;12(2):165-170.
40. Bae JS, Rhee WT, Kim WJ, et al. Clinical and radiologic analysis of posterior apophyseal ring separation associated with lumbar disc herniation. *J Korean Neurosurg Soc*. 2013;53(3):145-149.
41. Bernstein RM, Cozen H. Evaluation of back pain in adolescents. *Am Fam Physician*. 2007;76(11):1669-1676. Accessed February 4, 2020. <https://www.aafp.org/afp/2007/1201/p1669.html>

eFIGURE A



The Patrick (FABER) test. Note how the examiner has flexed, abducted, and externally rotated the child's right hip.

Reprinted with permission from Naranje S, Kelly DM, Sawyer JR. A systematic approach to the evaluation of a limping child. Am Fam Physician. 2015;92(10):908.